

<https://doi.org/10.31533/pubvet.v17n6e1402>

Efficacy of the association of homeopathy and autohemotherapy in the treatment of dogs with papillomatosis: Case report

Francielle Alves Caldato Busnardo¹, Talita Tomaz Nader², Aloísio Cunha de Carvalho^{3,4}, Ana Catarina Viana Valle^{3,4}

¹Autonomous Veterinarian, Uberaba, Brazil

²IPI, Ribeirao Preto, Brazil

³Doctor Izaio Soares Institute - IDIS/Lamasson, Ribeirao Preto, Brazil

⁴Natural Veterinary Medicine Institute – IMVN, Brasilia, Brazil

Corresponding author: cielle.medvet@gmail.com

Abstract. Canine papillomatosis is an infectious-contagious pathology caused by the species-specific papillomavirus, characterized by benign neoformations, which can be manifested in the oral cavity, genital tract, lips, pharynx, and esophagus. Sometimes, papillomas may occur in the plantar cushion and as cutaneous disease. Disease transmission occurs by direct or indirect contact with secretions or blood from papillomas present in infected animals. Diagnosis is based on clinical and histopathological examinations. This study aims to report the efficacy of the association of homeopathic medicines and autohemotherapy for treating a 4-month-old American Pit Bull Terrier male dog diagnosed with oral papillomatosis. The treatment protocol was based on the exclusive use of the homeopathic medicines *Kali sulphuricum*, *Thuya occidentalis*, and *Acidum nitricum*, associated with autohemotherapy. Complete remission of the papillomas occurred 30 days after treatment initiation, and the medication was maintained for six months to prevent a recurrence. In conclusion, homeopathy and autohemotherapy can reorganize defense cells, providing the body with evident clinical improvement.

Keywords: Clinical improvement, complementary therapy, *Thuya occidentalis*

Eficácia da associação de homeopatia e auto-hemoterapia no tratamento de cães com papilomatose: Relato de caso

Resumo. A papilomatose canina é uma patologia infectocontagiosa causada pelo papilomavírus espécie-específico, caracterizada por neoformações benignas, que podem se manifestar na cavidade oral, trato genital, lábios, faringe e esôfago. Às vezes, papilomas podem ocorrer no coxim plantar e cutâneo. A transmissão da doença ocorre pelo contato direto ou indireto com secreções ou sangue de papilomas presentes em animais infectados. O diagnóstico é baseado em exames clínicos e histopatológicos. Este estudo tem como objetivo relatar a eficácia da associação de medicamentos homeopáticos e auto-hemoterapia no tratamento de um cão macho American Pit Bull Terrier, de quatro meses de idade diagnosticado com papilomatose oral. O protocolo de tratamento baseou-se no uso exclusivo dos medicamentos homeopáticos *Kali sulphuricum*, *Thuya occidentalis* e *Acidum nitricum*, associados à auto-hemoterapia. A remissão completa dos papilomas ocorreu 30 dias após o início do tratamento, e a medicação foi mantida por seis meses para evitar recorrência. Em conclusão, a homeopatia e a auto-hemoterapia podem reorganizar as células de defesa, proporcionando ao organismo uma evidente melhora clínica.

Palavras-chave: Melhora clínica, terapia complementar, *Thuya occidentalis*

Eficacia de la combinación de homeopatía y autohemoterapia en el tratamiento de perros con papilomatosis: Reporte de caso

Resumen. La papilomatosis canina es una patología infectocontagiosa causada por el virus del papiloma específico de la especie, caracterizada por neoformaciones benignas, que pueden manifestarse en la cavidad bucal, tracto genital, labios, faringe, esófago, en algunos casos pueden presentarse papilomas en almohadillas plantares y papilomas cutáneos. La transmisión se produce por contacto directo o indirecto con secreciones o sangre de animales contaminados. El diagnóstico se basa en exámenes clínicos e histopatológicos. El objetivo de este trabajo es reportar el éxito del tratamiento integrador, asociando el uso de medicamentos homeopáticos con la autohemoterapia en el tratamiento de la papilomatosis oral en un perro American Pit Bull Terrier, de cuatro meses. El protocolo de tratamiento se basó en el uso exclusivo de los medicamentos homeopáticos *Kali sulfuricum*, *Thuya occidentalis* y *Acidum nitricum*, asociados a la autohemoterapia. La remisión completa de los papilomas se produjo a los 30 días de iniciado el tratamiento, manteniéndose la medicación durante seis meses para evitar la recurrencia. En conclusión, la homeopatía y la autohemoterapia pueden reorganizar las células de defensa, proporcionando al organismo una evidente mejoría clínica.

Palabras clave: Mejoría clínica, terapia complementar, *Thuya occidentalis*

Introduction

Papillomatosis is an infectious pathology caused by a species-specific virus called papillomavirus that belongs to the Papillomaviridae family ([Dias et al., 2013](#); [Fernandes et al., 2009](#)). It can manifest itself in isolated or multiple ways in different parts of the body ([Vieira & Poggiani, 2012](#)). According to [Queiroz et al. \(2015\)](#) and [Munday et al. \(2017\)](#), this disease most often affects puppies and young animals, in some rare cases immunosuppressed adults, characterized by the proliferation of warty masses, in most cases self-limiting.

According to [Ettinger et al. \(2017\)](#), disease transmission occurs by direct or indirect contact with secretions or blood from papillomas present in infected animals. [Hnilica & Patterson \(2011\)](#) and [Medleau & Hnilica \(2006\)](#) report that the incubation period may vary from one to two months and that lesion can remain in the dog's oral cavity for four to six months. The diagnosis is based on clinical and histopathological examinations, but the age of the animal, associated with the history, should be evaluated individually.

The literature suggests different therapeutic protocols to treat animal papillomatosis, such as surgical excision of lesions, electrosurgery, cryotherapy, administration of antiviral medications, homeopathic medicines, autohemotherapy, application of autogenous vaccine, immunomodulatory medicines, and systemic or intralesional chemotherapy sessions ([Dias et al., 2013](#)).

Homeopathy, developed by the German physician Samuel Hahnemann at the end of the 18th century, was first used for treating human diseases and, later, in animal species ([Carneiro et al., 2011](#); [Lucena Júnior et al., 2021](#); [Santos, 2014](#); [Souza, 2002](#)). Therefore, homeopathic medicines can be an alternative to treat various diseases, such as canine papillomatosis, because, with this therapy, it is possible to stimulate the nonspecific defenses of the organism, thereby promoting the elimination of the aggressor agent and the disappearance of lesions ([Custódio et al., 2017](#); [Werner et al., 2010](#)). An example is the medicine *Thuya occidentalis*, usually used in veterinary medicine to treat polyps, warts, comedones, papillomas, and follicular dermatosis. It is known in the homeopathy language as "The wart" ([Labrecque et al., 1992](#)).

Autohemotherapy was another therapeutic approach highly indicated to treat various diseases. It is a technique that restructures defense cells and provides the body with the capacity for self-healing. This technique emerged in Brazil in 1940 when Professor Jesse Teixeira proved that the phagocytic Mononuclear System was activated by autohemotherapy ([Borges et al., 2014](#)). This method consists of removing venous blood from the patient, followed by its immediate deep intramuscular application in the same patient, promoting nonspecific immune stimulation and increasing antibody levels ([Bambo et al., 2012](#)).

This case report aims to demonstrate the effectiveness of the exclusive use of homeopathy and autohemotherapy in treating a dog with canine oral papillomatosis, diagnosed through clinical and laboratory tests.

Material and methods

The patient consisted of a four-month-old male dog of the American Pit Bull Terrier breed, with an average weight of 12 kg (at the beginning of treatment), vaccinated, dewormed, fed with commercial dog food, and with the main complaint of warts in the oral cavity ([Figure I](#)). After clinical examination and laboratory tests, the patient received a diagnosis suggesting papillomatosis.

The treatment protocol was based on the exclusive use of oral homeopathic medicines and autohemotherapy. The following medicines were prescribed: *Kali sulphuricum* 200CH X/5, PO, single dose; *Acidum nitricum* 200CH, PO, five drops weekly; *Thuya occidentalis* 30CH, PO, five drops daily. Autohemotherapy consisted of collecting 20 mL of blood from the patient and then applying it intramuscularly once a week.

Results and discussion

The animal presented clinical symptoms of papillomatosis with warts in the oral cavity ([Figure I](#)); no hematological alterations were found in the first blood count. The first blood count was performed at the beginning of treatment on May 5th, 2016 ([Table 1](#)). No other tests were performed to evaluate the other parameters. At 14 days of treatment initiation, a significant clinical improvement of the lesions was observed ([Figures IIA](#) and [IIB](#)). A new blood count was performed on June 25th, 2016 ([Table 1](#)), after 30 days of treatment initiation, to monitor the patient's health status, showing clinical improvement of the lesions initially presented and complete resolution of the case ([Figures IIC](#) and [IID](#)).

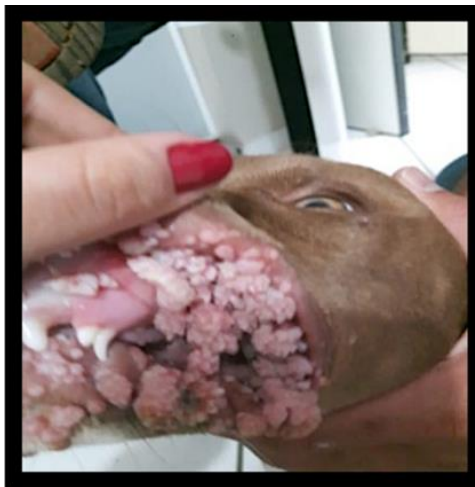

Figure I. Aspect of lesions in the patient's oral cavity.

The homeopathic medicines were chosen due to their anatomopathological similarity. The chosen protocol continued to be administered to the animal for five months to avoid recurrence. During this period, a new blood count was performed on November 10th, 2016 ([Table 1](#)), after the end of the treatment, to verify the patient's overall health status.

Thuya occidentalis is a medicine routinely used in homeopathic and herbal treatments in human and veterinary medicines, presenting various indications. The action of the *Thuya* alcoholic tincture seems to be related to the presence of a volatile oil in its composition that is an immunostimulant and blood purifier. Therefore, the mother tincture of the *Thuya occidentalis* plant can be topically used in papillomas ([Dias et al., 2013](#); [Queiroz et al., 2015](#)). [Lira et al. \(2012\)](#) and [Queiroz et al. \(2015\)](#) reported the use of *Thuya occidentalis* 30CH to treat papillomas successfully. Additionally, [Queiroz et al. \(2015\)](#) recorded good results in treating this disease using *Nitricum acidum* 30CH and *Nitricum acidum* D3.

[Valle \(2021\)](#) reported excellent and quick results in treating oral papillomatosis in two dogs using homeopathy, associating *Thuya occidentalis* and *Viscum album* with autohemotherapy. Similarly, to

[Lira et al. \(2012\)](#), [Queiroz et al. \(2015\)](#) and [Valle \(2021\)](#), the *treatment* proposed in this report achieved its purpose by quickly and effectively reestablishing the integrity of the patient's oral mucosa. It was considered a low-cost treatment with no side or adverse effects. Despite the controversies regarding the protocols chosen in this case report, the approach based on correcting immunosuppression as a primary cause is fundamental for treatment success.

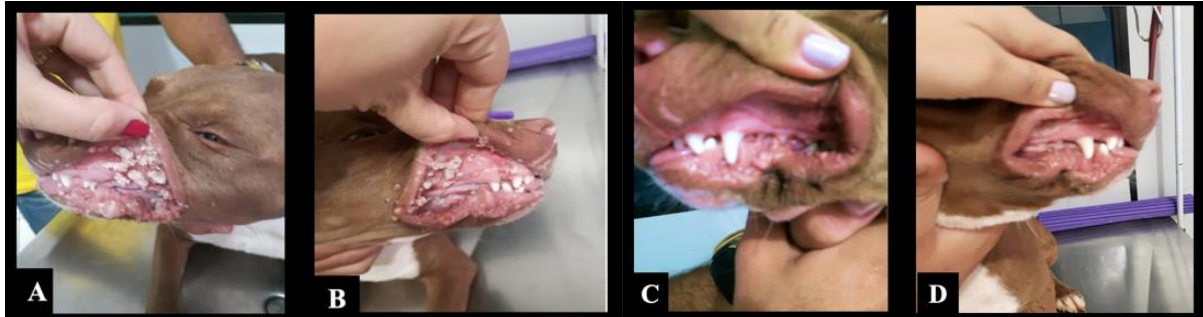


Figure II. A and B. Aspect of the patient's lesions, showing 50% improvement of symptoms after 15 days of treatment; C and D. Complete remission of papillomas after 30 days of treatment, with 100% improvement of clinical signs.

Table 1. Serum blood of dog from 4-month-old and references values

Blood count	Results			Reference value
	May 5th, 2016	June 25th, 2016	November 10th, 2016	
Red blood cells	4.0	5.4	6.0	5.5 – 7.0 (million/mm ³)
Hematocrit	31.4	34.6	38.6	34 – 47 (%)
Hemoglobin	11.5	12.4	14.4	11 – 17 (g%)
MCV	78.5	64.1	70.1	65 – 78 (u ³)
MCH	28.7	23.0	23.0	20 – 25 (uug)
MCHC	36.6	35.8	34.8	30 – 35 (g%)
Platelets	141,000	318,000	330,000	200 – 500 (mm)
Total Leukocytes	17,200	11,100	11,200	8,000 – 16,000 (thousand/mm ³)
Rod neutrophils	16	1	2	0 – 1 (%)
Eosinophils	8	10	4	1 – 6 (%)
Basophils	3	0	1	0 – 1 (%)
Typical Lymphocytes	40	46	35	28 – 45 (%)
Atypical Lymphocytes	0	0	0	0 (%)
Monocytes	8	10	5	1 – 10 (%)

Therefore, this study proved effective in treating canine papillomatosis, although the medicines used differed from those suggested in the literature. The association of these homeopathic medications *with* autohemotherapy improved the patient's clinical condition in the expected time, in addition to increasing immunity, proven by blood counts performed before, during, and after treatment, which led to effective clinical improvement.

Conclusions

Thuya occidentalis, *Kali sulphuricum*, and *Acidum nitricum* associated with autohemotherapy were used as immunostimulants to treat canine oral papillomatosis and proved effective in the recovery of the patient and the fast remission of clinical signs. In addition, they also proved to stimulate the patient's immune system, as the animal showed improvement in cell counts, thus showing restoration of the patient's entire organism.

References

- Bambo, O., Cardoso, J. M. M., Dimande, A., & Santos, I. F. C. (2012). Auto-hemoterapia no tratamento da papilomatose oral canina–Relato de caso. *Revista de Educação Continuada Em Dermatologia e Alergologia Veterinária*, 2(2), 39–43.
- Borges, O. M. M., Souza, A. P., Mendes, R. S., Araújo, K. N., Torres, L. M., & Dantas, A. K. F. P. (2014). Clinical effectiveness of autohemotherapy as an adjunct treatment of canine parvovirus. *Acta Scientiae Veterinariae*, 42(1), 1–7.

- Carneiro, S. M. T. P., Teixeira, M. Z., Nechar, R. M. C., Lonni, A. A., Rodrigues, M. R., & Filippesen, L. (2011). Homeopatia: princípios e aplicações na agroecologia. In *Londrina: IAPAR*. IAPAR.
- Custódio, E., Baldissera, M. D., Machado, G., Cazarotto, C. J., Boito, J. P., Biazus, A. H., Galli, G. M., Reis, J. H., Gebert, R. R., & Ferreira, E. B. (2017). Use of homeopathic product to prevent ketosis in the dairy sheep during the transition period. *Comparative Clinical Pathology*, 26(3), 535–541.
- Dias, F., Pereira, L., Cintra, C., Honsho, C., & Dias, L. G. (2013). Papilomatose oral em cães. *Enciclopédia Biosfera*, 9(17), 2008–2018.
- Ettinger, S. J., Feldman, E. C., & Cote, E. (2017). *Textbook of Veterinary Internal Medicine-eBook*. Elsevier Health Sciences.
- Fernandes, M. C., Ribeiro, M. G., Fedato, F. P., Paes, A. C., & Megid, J. (2009). Papilomatose oral em cães: revisão da literatura e estudo de doze casos. *Semina: Ciências Agrárias*, 30(1), 215–224. <https://doi.org/10.5433/1679-0359.2009v30n1p215>.
- Hnilica, K. A., & Patterson, A. P. (2011). *Small animal dermatology: a color atlas and therapeutic guide*. Elsevier Health Sciences.
- Labrecque, M., Audet, D., Latulippe, L. G., & Drouin, J. (1992). Homeopathic treatment of plantar warts. *CMAJ: Canadian Medical Association Journal*, 146(10), 1749–1753.
- Lira, R. N., Lempek, M. R., Marinho, P. V. T., Neves, C. C., & Trombini, H. R. (2012). Uso de Thuya occidentalis no tratamento da Papilomatose oral canina. *PUBVET*, 6(16), Art-1357. <https://doi.org/10.22256/pubvet.v6n16.1360>.
- Lucena Júnior, L. C., Lopes, E. B., Santos, C. M., Valois, A. A. C., Menezes, N. J., Santana, S. S., & Lima, I. S. S. (2021). Tratamento integrativo homeopático e farmacopuntura com *Viscum album* em carcinoma mamário canino: Relato de caso. *PUBVET*, 15(6), 1–9. <https://doi.org/10.31533/pubvet.v15n06a835.1-9>.
- Medleau, L., & Hnilica, K. A. (2006). *Small animal dermatology*. Editora Roca.
- Munday, J. S., Thomson, N. A., & Luff, J. A. (2017). Papillomaviruses in dogs and cats. *The Veterinary Journal*, 225, 23–31. <https://doi.org/10.1016/j.tvjl.2017.04.018>.
- Queiroz, F. F., Rodrigues, A. B. F., Di Filippo, P. A., Almeida, A. J., & Silveira, L. S. (2015). Thuya occidentalis CH12 as an alternative treatment to dog papillomatosis. *Revista Brasileira de Plantas Mediciniais*, 17, 945–952. https://doi.org/10.1590/1983-084x/14_111.
- Santos, R. (2014). Homeopatia: histórico e fundamentos. *Revista Científica da Faculdade de Educação e Meio Ambiente*, 5, 60–78.
- Souza, M. F. A. (2002). Homeopatia veterinária. *Conferência Virtual Global Sobre Produção Orgânica de Bovinos de Corte*, 1, 1–4.
- Valle, A. C. V. (2021). Homeopathic treatment of oral papillomatosis in dogs (*Canis familiaris*)-Case report. *International Journal of Sciences and Research*, 10(9), 487–491.
- Vieira, L. C., & Poggiani, S. S. C. (2012). Papilomatose canina. *PUBVET*, 6(16), Art. 1357.
- Werner, C., Sobiraj, A., & Sundrum, A. (2010). Efficacy of homeopathic and antibiotic treatment strategies in cases of mild and moderate bovine clinical mastitis. *Journal of Dairy Research*, 77(4), 460–467.

Histórico do artigo:**Recebido:** 28 de maio de 2023**Aprovado:** 3 de junho de 2023**Licenciamento:** Este artigo é publicado na modalidade Acesso Aberto sob a licença Creative Commons Atribuição 4.0 (CC-BY 4.0), a qual permite uso irrestrito, distribuição, reprodução em qualquer meio, desde que o autor e a fonte sejam devidamente creditados.