



ORIGINAL RESEARCH PAPER

Veterinary Science

PSYCHOGENIC DERMATITIS IN A CORGI DOG TREATED BY INJECTABLE HOMEOPATHY - CASE REPORT

KEY WORDS: acral dermatitis, separation anxiety, homeopathic therapy.

Ana Catarina Viana Valle*

IDIS/Lamasson, 96 Americo Brasiliense Ave, Ribeirao Preto, SP, Brazil, 16.000-000. *Corresponding Author

Aloísio Cunha de Carvalho

IDIS/Lamasson, 96 Americo Brasiliense Ave, Ribeirao Preto, SP, Brazil, 16.000-000

ABSTRACT

Skin problems in dogs represent a daily important casuistic in veterinary practices. They affect both young and adult animals and may have varied causes, challenging the correct diagnosis. Within this context, it should be emphasized the close coexistence and attachment to their owners who play a crucial role in the development and treatment of part of the so-called psychogenic dermatitis. This type of illness must be understood as a multifactorial problem that requires a lot from all parties involved to be an effective therapy for the patient. Several medicines are indicated for the treatment, but most of them cause long-term side effects. For these reasons, different therapies, such as homeopathy, should be considered as alternative treatments. This article aimed to report a psychogenic dermatitis case in a 10-year-old male dog suffering from separation anxiety, which led to the development of a compulsive licking behavior. The patient was treated with injectable homeopathic medicines, and excellent results were recorded in a short period.

INTRODUCTION

Acral dermatitis or acral licking dermatitis is characterized as one of the most common behavioral disorders associated with dermatological changes in dogs. It results in the so-called psychogenic dermatitis, which causes skin lesions (Shumaker, 2019) of recurrent pattern, being resistant to various therapies. It is considered as corresponding to obsessive-compulsive disorder (OCD) in humans (Larsson et al., 1985; Muller et al., 1985). Goldeberger and Rapoport (1991) characterize OCD in humans as having two components: obsession and compulsion. They understand that one's obsessive-compulsive behavior is irrational and very little can be done to control this behavior, increasing one's suffering (Goldeberger & Rapoport, 1991; Scott et al., 2001).

The etiology of such behavioral changes within Veterinary Medicine is still far from being known, but it is known that it is directly linked to the behaviors of the owners and their constant changes in routine. Within this subject, separation anxiety is a growing problem within the small animal practice. It is difficult to treat given the modern lifestyle with few flexible habits and routines on the part of the owners. A behavioral disorder or stereotyped behavior becomes evident when an animal shows constant repetitions of a gesture or insignificant behavior pattern, and this action is recognized by the owner as abnormal (Wilkinson & Harvey, 1997).

Behavioral therapy has unique aspects within Veterinary Medicine, starting with the participation of the owner in assisting in the discovery of the diagnosis and treatment, and being one of the fundamental therapeutic agents (Pereira, 1996). It may or may not be associated with drug treatment, which can later be harmful to veterinary patients because there are generally long-term side effects. Therefore, complementary therapies should be considered associated with management modification by the owners (Valle & Carvalho, 2022).

Homeopathy is a therapy that aims to treat the patient in its entirety, both the physical and the mental parts. The latter is highlighted by the effectiveness of treatments of behavioral disorders in dogs and cats (Teixeira, 2008). According to Teixeira (2008), homeopathy can act specifically in the treatment of behavioral disorders, modulating individual susceptibilities and valuing the emotional and psychological manifestations described in the experimentation of medicinal substances in a healthy individual. For this reason,

homeopathy should be considered to treat mental disorders in dogs and cats.

This article aims to report the occurrence of psychogenic dermatitis in a 10-year-old male corgi dog suffering from separation anxiety, who was treated with injectable homeopathic therapy and showed an excellent response to the treatment.

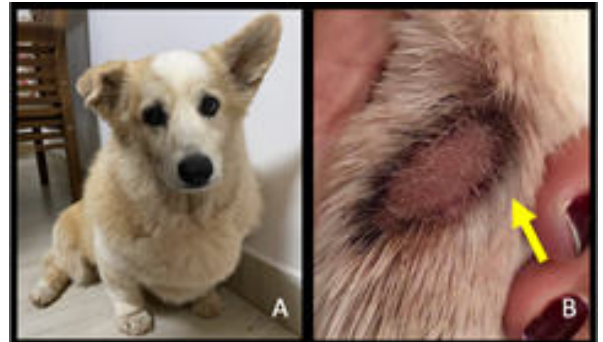


Figure 1. A) A 10-year-old Corgi male dog, neutered. B) Yellow arrow indicates an initial skin lesion (acral dermatitis).

CASE REPORT

A 10-year-old Corgi male dog, neutered, and weighing 16 kg (Figure 1A) was seen at NaturalPet, Brasilia, Brazil. The patient had a history of persistent licking on the lateral side of the right forelimb, which had already caused local skin injury and loss of fur. As stated by the owner, the animal started the licking behavior two days after her daughter had traveled. This behavior became persistent, culminating in skin injury after three days. She reported that the dog considered her daughter to be his real owner and he was very attached to her. According to her, the animal remained in a mild depressive state (sad) and he was not happy as usual. In addition, the patient displayed quiet behavior most of the time. However, he was more anxious when her daughter was out and stayed downstairs waiting for her to return home. She denied grudge, mania, loquacity, aggressiveness, hurt, disguised behavior, or any exacerbated behavioral change in his routine. On physical examination, the animal was alert, mucous membranes were normal, CRT 2", blood pressure 12X8, heart rate 120 bpm, and Temperature 38.5 °C. As mentioned by the owner, the right forelimb had a lesion with small crusts and a certain amount of continuity solution. Given what was exposed by the owner, the animal considered her

daughter as the real owner. However, the latter had traveled, triggering the compulsive behavior by the animal, which was clinically diagnosed after physical examination and anamnesis as acral licking dermatitis caused by separation anxiety syndrome. A protocol using injectable homeopathic medicines was established, mainly due to the easy and fast administration, as well as the fact that it does not cause side effects. The patient was medicated using the following medicines: Rhus tox D8 +D35 (Injectcenter), 1 ampoule (1.1mL), subcutaneously, once a day for 7 days; and Crataegus D4 + D8 (Injectcenter), 1 ampoule (1.1mL), subcutaneously, once a day for 20 days. Topical use of 1% chlorhexidine-based antiseptic spray was also prescribed, being administered 1 spray, twice a day, for 7 days.

RESULTS

The patient showed progressive improvement after treatment initiation (Figure 2A), decreasing the licking behavior. Granulation tissue was formed at the edges of the wound (Figure 2B) four days after treatment initiation. Subsequently, according to the photographic records (Figures 2C and D), the improvement occurred quickly and efficiently. The total lesion resolution occurred in 15 days and complete growth of fur in the site was accomplished in 70 days (Figure 2E). The patient's real owner returned from travel 17 days after the onset of clinical signs.

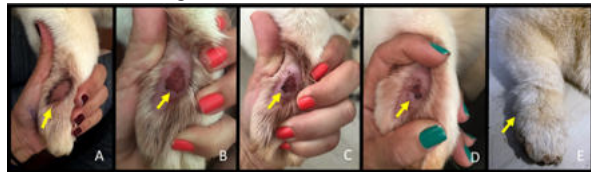

Figure 2. The yellow arrows indicate A) Initial skin lesion (acral dermatitis); B) Lesion aspect four days after treatment initiation. Granulation tissue is also noted around the lesion; C) Lesion aspect seven days after treatment initiation; D) Lesion aspect four days after treatment initiation; E) Lesion aspect 70 days after treatment initiation.

DISCUSSION

Psychogenic dermatitis can be caused by the constant licking of a certain site, resulting in a lesion called acral dermatitis. This lesion is characterized by moist granulomatous, erythematous, and alopecic plaque, often located in the forelimbs, which can be easily and comfortably licked by the animal (Landsberg, 2004). Its etiology is unknown, but environmental and mental factors may contribute to the development of this problem. A possible explanation for the emergence of this behavior is the routine of the owners who require the animals to be alone for a long time, receiving less and less attention. Moving to another house, trips, and routines may also trigger this behavior (Scott et al., 2001).

The treatment of psychogenic dermatitis is complex and involves several factors, correcting the triggering factor being the main one. Therapy includes changes in environmental and behavioral management, associating antidepressants, anxiolytics, corticosteroid therapy, cryosurgery or surgical excision, and radiotherapy, among others (Costa, 2008). In general, conventional therapy aims to treat the clinical signs and not exactly the cause of the behavior. Therefore, even with long-term medication, disease control can be prolonged for a lifetime, and the onset of side effects will be inevitable (Torro et al., 2004). However, less invasive therapies focused on treating the cause of the pathology should be emphasized (Valle & Carvalho, 2022).

Within this context, homeopathy, enunciated by Hippocrates and developed by Samuel Hahnemann, excels the body's reaction by stimulating its vital energy as a pathway to self-healing (Brunini, 1993; Benites, 2000). It uses medicines capable of stimulating the body mentally and physically,

prescribed after a detailed analysis of the case. In general, homeopathy has been practiced within medical offices for more than 200 years, and excellent results are recorded. The studies in a systematized way began with the aim of proving scientifically the effects of homeopathic medicines. The results have shown excellent efficacy and constancy (Belon et al., 1999; Bonamin et al., 2001; Demangeat et al., 1997; Youbicier et al., 1993; 1997;). Hence, it becomes a scientific-based therapy that is safe for administration in sick patients, especially in the patient's psychosomatic profile. It is, thus, an important tool to allow a broad and effective approach to patients with psychosomatic dermatitis (Torro et al., 2004).

Scott et al. (2001) emphasize that emotional factors are generally so important in skin diseases that, if ignored, the treatment of approximately 40% of patients may not be possible. In a study conducted by Torro et al. (2004), 77 animals diagnosed with acral licking dermatitis were submitted to homeopathic treatment with the medicines Pulsatilla, Lachesis, Calcarea, Arsenicum, Belladonna, Ignatia, Lycopodium, Phosphorus, and Stramonium. Pulsatilla, which is indicated for patients who require a large amount of affection, was prescribed in 40% of the cases. Lachesis was indicated in 15% of the cases; Calcarea and Arsenicum were prescribed for 10% of patients; and Belladonna, Ignatia, Lycopodium, Phosphorus, and Stramonium were prescribed in 5% of the cases. Dogs became asymptomatic in the 3rd month of treatment in 65% of the cases while 85% had remission of clinical signs up to 6 months of treatment. According to the authors, the success of the therapeutic protocols was evident because total healing and complete fur coating of injured areas were obtained in 74% of the dogs.

The present article corroborates Scott et al. (2001) and represents another case of acral dermatitis caused by emotional factors, which were considered for its treatment. For this purpose, we used homeopathic medicines that encompassed the patient's mental sphere and, for this reason, excellent results were obtained. The present study is also in line with Torro et al. (2004), who recorded the successful use of homeopathic medicines to treat patients with acral licking dermatitis. Our study proves that the results may be promising when the medicines are well chosen, taking into account the mental environment associated with the physical environment.

The medicines chosen in this study were Rhus toxicodendron (Rhus tox) and Crataegus oxyacantha. For a better approach, the emotional aspect prevailed, and then the physical aspect, considering that these medicines involve the syphilitic miasma. The individuality both desired and emphasized in choosing homeopathic treatment protocols is thereby reaffirmed, as it can be seen in the experiment carried out by Torro et al. (2004), when they used several medicines for the same purpose, obtaining equally success, only with the difference in recovery time.

Rhus tox, one of the medicines chosen in the present case, is derived from a plant and belongs to the European continent. It is well known for its extensive activity in various organic systems, showing great action on the skin. Its sphere of mental action comprises extreme anxiety, intense agitation, melancholy, sadness, and shyness, which trigger depressive behavior, in many cases, due to their dissatisfaction with certain situations. Furthermore, its activity on the skin is specified by urticaria, among others (Lathoud, 2017). Crataegus oxyacantha is a plant-derived medicine that originated in the European continent. Its main and best-known activity is in the cardiovascular system. It has vasodilating, relaxing, and antioxidant actions, stimulating blood circulation and healing skin and mucous membranes (Stelmakiene et al., 2016). However, it can also act in apprehensive, discouraged, and choleric individuals with mental apathy (Lathoud, 2017).

Therefore, it is evident that the treatment of dermatitis goes beyond a drug treatment, aiming at the physical condition of patients. The treatment comprises a set of actions, firstly, to achieve the diagnosis with the elimination of several causal agents, and the institution of the proper treatment protocol. Homeopathic therapy is enlightening bearing in mind the medicine availability that acts in the mental and physical sphere of the treated patients, which fits uniquely in the treatment of psychogenic dermatitis. Furthermore, it is necessary to mention the important collaboration of the owners as partners in this therapy. All these factors above-mentioned are of paramount importance for the success of most dermatological problems in dogs and cats, whether they are punctual or recurrent.

CONCLUSION

In conclusion, the present study reports another successful treatment using homeopathy. It shows the efficacy of a low-cost therapy that considers the physical and mental symptoms of the patient, with the absence of side effects in addition to fast resolution of the problem.

REFERENCES

1. Belon, P., Cumps, J., Ennis, M., Mannaioni, P.F., Sainte-Laudy, J., Roberfroid, M., & Wiegant, F. A. (1999). Inhibition of human basophil degranulation by successive histamine dilutions: results of a European multi-centre trial. *Inflammation research : official journal of the European Histamine Research Society ... [et al.]*, 48 Suppl 1, S17-S18. <https://doi.org/10.1007/s00110050376>
2. Benites, N. R. (2000). Estudo da força vital estimulada por medicação homeopática através do emprego da matéria médica. *Clínica Veterinária*, no/dez.2000(29), 36-40.
3. Bonamin, L. V., Martinho, K. S., Nina, A. L., Caviglia, F., & Do Rio, R. G. (2001). Very high dilutions of dexamethasone inhibit its pharmacological effects in vivo. *The British homeopathic journal*, 90(4), 198-203. <https://doi.org/10.1054/homp.1999.0496>
4. Brunini, C. (1993). *Homeopathy: principles, doctrine and pharmacy*. Sao Paulo, Mythos Press.
5. Costa, A. T. (2008). Acral dermatitis caused by licking in dogs. Undergraduate thesis, Faculdade Metropolitana Unidas, Sao Paulo, SP, Brazil.
6. Demangeat, J.L., Gries, P., & Poitevin, B. (1997). Modification of 4 Mhz N.M.R. Water Proton Relaxation Times in Very High Diluted Aqueous Solutions: Signals and Images. Dordrecht, Springer. https://doi.org/10.1007/978-94-011-5804-6_8
7. Goldeberger, E., & Rapoport, J. L. (1991). Canine acral lick dermatitis: Response to the antiobsessional drug clomipramina. *Journal of the American Animal Hospital Association*, 27, 179-182.
8. Landsberg, G., Hunthausen, W., & Ackerman, L. (2004). *Behavior problems of the dog and cat*. São Paulo, Roca.
9. Larsson, C. E., Carpinete, S. C., & Larsson, M. H. M. A. (1985). Psychogenic dermatitis diagnosed in dogs from Sao Paulo. *Revista Brasileira de Medicina Veterinária*, 7(5), 140-143.
10. Lathoud, J. A. (2017). *Studies on the Homeopathic Materia Medica*. Organon Press, Sao Paulo.
11. Muller, G.H., Kirk, R.W., & Scott, D.W. (1985). *Psychogenic Skin Diseases: Small Animal Dermatology* (chapter 16, p. 659-665). São Paulo, Manole Press.
12. Pereira, J.T. Contribution to the study of dermatitis caused by licking in dogs. (1996). Doctorate dissertation, University of Sao Paulo, São Paulo, SP, Brazil.
13. Scott, D. W., Miller, H. W., & Griffin, C. E. (2001). *Small Animal Dermatology*. Saunders Press.
14. Shumaker A. K. (2019). Diagnosis and treatment of canine acral lick dermatitis. *The Veterinary clinics of North America. Small animal practice*, 49(1), 105-123. <https://doi.org/10.1016/j.cvsm.2018.08.010>
15. Stelmakiene, A., Ramanauskiene, K., Petrikaite, V., Jakstas, V., & Briedis, V. (2016). Application of dry hawthorn (*Crataegus oxyacantha* L.) extract in natural topical formulations. *Acta poloniae pharmaceutica*, 73(4), 955-965.
16. Teixeira, M. Z. (2008). Clinic research in homeopathy: evidences, limitations and projects. *Pediatrics*, 30(1), 27-40.
17. Torro, A. R., Larsson, C. E., & Bonamin, L. (2004). Homeopathy and psychogenic alopecia: clinical study. *Revista Brasileira Ciência Veterinária*, 11(3), 147-151.
18. Valle, A. C. V., & Carvalho, A. C. (2022). Treatment of bladder uroliths in a dog by injectable homeopathy. *International Journal of Scientific Research*, 13(01(B)):78-81.
19. Wilkinson, G.T., & Harvey, R.G. (1997). *Psychogenic Skin Diseases: Color atlas of small animal dermatology: a guide to diagnosis* (chapter 16, p. 255-256). Sao Paulo, Manole.
20. Youbicier, B. J., Boudard, F., Oberbaum, M., Bastide, M., & Bayle, J. D. (1993). Effects of embryonic bursectomy and in ovo administration of highly diluted bursin on adrenocorticotrophic and immune response of chickens. *International Journal of Immunotherapy*, 9, 169-180.
21. Youbicier, B. J., Boudard, F., Guellati, M., Mekaouche, M. Baylé, J. D., & Bastide, M. (1997). The role of the Bursa de Fabricius and highly dilute bursin in immunoendocrine interactions in the chickens: Signal and Images. Dordrecht, Kluwer Academic Publisher.