

# Homeopathy for the Treatment of Transmissible Venereal Tumor (TVT) in a Mixed-Breed Female Dog

Ana Catarina Viana Valle<sup>1,2\*</sup>, Marcelo Sibata<sup>2</sup>, Rosangela Vieira Andrade<sup>1</sup> and Aloísio Carvalho<sup>3</sup>

<sup>1</sup>Catholic University/Department of Genetics and Biotechnology, Brasilia, Brazil

<sup>2</sup>Doctor Iza Soares Institute/ Department of Veterinary Homeopathy, Ribeirao Preto, Brazil

<sup>3</sup>Paulista University/Department of Experimental Pathology, Sao Paulo, Brazil

ISSN: 2637-7802



\*Corresponding author: Ana Catarina Viana Valle, Brasilia, DF, Brazil, Email: [dranacatarina@gmail.com](mailto:dranacatarina@gmail.com)

Submission:  July 16, 2019

Published:  July 19, 2019

Volume 5 - Issue 1

**How to cite this article:** Ana Catarina Viana Valle, Marcelo Sibata, Rosangela Vieira Andrade, Aloísio Carvalho. Homeopathy for the Treatment of Transmissible Venereal Tumor (TVT) in a Mixed-Breed Female Dog. *Adv Complement Alt Med.* 5(1). ACAM.000602.2019. DOI: [10.31031/ACAM.2019.05.000602](https://doi.org/10.31031/ACAM.2019.05.000602).

**Copyright@** Ana Catarina Viana Valle. This article is distributed under the terms of the Creative Commons Attribution 4.0 International License, which permits unrestricted use and redistribution provided that the original author and source are credited.

## Abstract

The transmissible venereal tumor (TVT) is a neoplasm, and its diagnosis is based on clinical, cytological and/or histopathological examination. Vincristine sulfate is the conventional treatment of choice. However, homeopathy is also a therapeutic possibility by the use, for example, of *Viscum album*, which has been employed in the treatment of cancer. A 2-year-old mixed-breed female dog diagnosed with TVT was orally treated with *Thuya occidentalis* 1x10<sup>-12</sup>; topical application of *T. occidentalis* 1x10<sup>-18</sup> in the lesion; and *V. album* subcutaneous applications in different dilution combinations (1x10<sup>-3</sup>, 1x10<sup>-6</sup>, 1x10<sup>-9</sup>, 1x10<sup>-12</sup>, 1x10<sup>-30</sup>). The tumor mass was reduced in about 90% during 150 days of treatment, and the patient had no longer bloody vaginal discharge. The complete remission of the tumor mass was accomplished with a single vincristine application (0.025mg Kg<sup>-1</sup>). No tumor mass was observed a week later, and the cytological examination confirmed the absence of tumor cells. No side effects were verified during the treatment period.

**Keywords:** *Viscum album*; *Thuya occidentalis*; Tumor remission

## Introduction

Transmissible venereal tumor (TVT) is a neoplasm characterized by the mechanical implantation of tumor cells in a healthy tissue by coitus [1]. The clinical signs are increased volume in the genital area accompanied by bloody discharge [2]. The diagnosis is based on clinical, cytological, and/or histopathological examination. The treatment of choice is performed with the chemotherapeutic vincristine sulfate. However, different therapies can be used, such as radiotherapy, surgical excision, immunotherapeutic, auto-hemotherapy, among others [2].

Homeopathy is also a therapeutic possibility, which can be established as a single treatment or associated with chemotherapy [3]. According to these authors, the association of homeopathic and chemotherapeutic medicines reduces the treatment time to which the animal is subjected, reducing the vincristine application frequency.

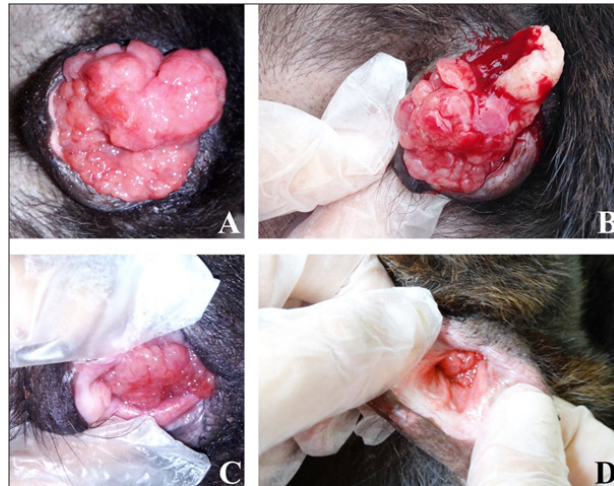
Homeopathy was created by the German physician Samuel Hahnemann. It is based on the law of similars and may be indicated for treating several neoplasms. *Thuya occidentalis*, the most cited medicine, is well-known for its therapeutic action in numerous pathologies [3]. In this context, *Viscum album* is gaining emphasis in oncological treatments due to the cytotoxic action of viscotoxins and lectins, some of its pharmacologically active compounds. The mechanism of action of these substances has not yet been elucidated, but it is known that lectins act in the cell membrane inducing apoptosis whereas viscotoxin induces rapid cell death by necrosis [4].

The combination of injectable *V. album* and vincristine has been reported to be effective as a therapy for TVT treatment in dogs, reducing the time of chemotherapeutic treatment and the leucopenia produced by the vincristine administration [5]. This study aimed to report the use of the homeopathic medicines *V. album* and *T. occidentalis*, in the TVT treatment of a mixed-breed female dog, for 150 days.

## Material and Methods

A 2-year-old mixed-breed female dog, weighing 9.5Kg, was attended on November 2014 at Natural Pet - Integrative Veterinary Clinic (Brasilia, DF, Brazil). The animal gave birth in the previous two months and presented persistent vaginal bleeding since then. In the first clinical evaluation, increased volume of the vaginal canal (4.9cm x 4.7cm) associated with bloody vaginal secretion were verified. The diagnosis of TVT was confirmed by vaginal cytology. Hemogram analyses were normal. Oral administration of *T. occidentallis*  $1 \times 10^{-12}$ , three times a day, and topical application of

*T. occidentallis*  $1 \times 10^{-18}$  in the lesion site, once-per-day, were initially prescribed. After seven days (Figure 1A), the *V. album* injectable therapy was started. The treatment consisted of one subcutaneous application of *V. album* per day. *V. album* applications followed a predetermined sequence of different potencies, as described: day 1)  $1 \times 10^{-3} + 1 \times 10^{-12}$ ; day 2)  $1 \times 10^{-6} + 1 \times 10^{-30}$ ; day 3)  $1 \times 10^{-3} + 1 \times 10^{-9}$ ; day 4)  $1 \times 10^{-6} + 1 \times 10^{-12}$ ; day 5)  $1 \times 10^{-9} + 1 \times 10^{-30}$ . This sequence was performed intermittently for 30 days. From the second month onwards, *V. album* applications were performed on alternate days, following the same administration sequence described above.



**Figure 1:** Transmissible venereal tumor (TVT) reduction in a mixed-breed female dog as a response to *Thuya occidentallis* and *Viscum album* after 7(A), 30(B), 90(C), and 150(D) days after treatment beginning.

## Results

A reduction of the tumor mass to 3.0cm x 2.3cm was observed at the end of the first treatment phase, which lasted 30 days (Figure 1B). From the second month onwards, *V. album* was applied on alternate days and, after 30 days, the tumor diameter was reduced to 2.0cm x 2.0cm. After 90 and 150 days of treatment, the tumor mass measured 1.0cm x 0.9cm (Figure 1C) and 0.5cm x 0.4cm (Figure 1D), respectively. The animal no longer had bloody vaginal secretion. At this time, a single vincristine application ( $0.025 \text{mgKg}^{-1}$ ) was performed to complete remission of the tumor mass and completion of the treatment.

The clinical examination was performed one week later, and no tumor mass was observed in the vaginal canal of the dog. The absence of tumor cells in the sample collected was confirmed by cytological examination. The animal had overall good health, and side effects were not manifested during the treatment period.

## Discussion

TVT is the most common neoplasm that affects the external genitalia of dogs and one of the causes of higher demand for veterinary care. TVT incidence is high in Brazil due to the tropical climate and large number of stray and sexually active dogs [1]. Several therapies are proposed for the treatment of this disease, such as chemotherapy, radiotherapy, immunotherapy, surgical excision, homeopathy, among others.

Chemotherapy is the therapeutics of choice for this pathology, and vincristine sulfate is used as the single medication, which is weekly administered. However, chemotherapy side effects and the increased reports of patient resistance to vincristine therapy, have stimulated the search for new and useful substances against TVT (Carvalho, 2010). According to this author, studies have shown that the association of vincristine with ivermectin or homeopathic and herbal medicines, which promote immunostimulation, may reduce the application number of the chemotherapeutic and also its side effects.

In this study, the homeopathic medicines *V. album*, subcutaneously injected, and *T. occidentallis*, orally administered, reduced about 90% of the tumor mass during 150 days of treatment, with no manifestation of side effects. These results conform with those of Lefebvre et al. [5], who also observed no side effects in the patient when using injectable *V. album* to reduce tumor size.

The prescription of *T. occidentallis* was due to pathogenetic and diathetic similarity [6,7], aiming at a complementary treatment. Manhoso et al. [3] and Santos et al. [1] also reported satisfactory results when using *T. occidentallis* for TVT treatment. The significant reduction observed in the tumor mass substantially minimized the use of vincristine. Therefore, only one application of this chemotherapeutic was required for complete resolution of the disease.

## Conclusion

*V. album* and *T. occidentalis* proved to be important therapeutic tools for the treatment of canine TVT. *T. occidentalis* oral and topical administration associated with *V. album* injectable therapy significantly reduced the tumoral manifestation of the disease, with no side effects, such as leucopenia. The patient's overall health was preserved, and the quality of life was improved. However, further studies are needed to fully understand how homeopathic medicines act in the treatment of this disease.

## References

1. Santos MP, Ladir EC, Moraes JC, Ferreira FA (2006) Use of homeopathy in the treatment of transmissible venereal tumor in a mixed-breed female dog - Case Report. *Veterinária Notícias* 12(2): 138.
2. Vural SA, Haziroglu R, Vural MR, Polat IM, Tunc AS (2018) Detection of progressive and regressive phase and LINE-1 retrotransposon in transfected dogs with transmissible venereal tumor during chemotherapy. *J Vet Sci* 19(5): 620-626.
3. Manhoso FFR, Pichini E, Santos PCG, Silva GI, Lombardi E, et al. (1997) Homeopathy and chemotherapy use in contagious venereal tumour treatment and its hematological aspects. *Pesq Homeop* 12(2): 50-64.
4. Werthmann PG, Huber R, Kienle GS (2018) Durable clinical remission of a skull metastasis under intralesional *Viscum album* extract therapy: Case report. *Head Neck* 40(7): 77-81.
5. Lefebvre GNF, Bonamin LB, Oliveira CM (2007) Treatment of transmissible venereal tumor (TVT) using *Viscum album* in combination with chemotherapy. *Rev Clin Vet* 70: 78-86.
6. Lopes DF (2008) *Viscum album* cytotoxicity in Caco-2 cells (*in vitro*) analyzed by Dispersive Raman Spectroscopy. *Int J High Dilution Res* 7(23): 7778.
7. Vannier L, Poirier J (1987) *Tratado de Matéria Médica Homeopática*. Andrei, São Paulo, Brazil, p. 448.

For possible submissions Click below:

[Submit Article](#)